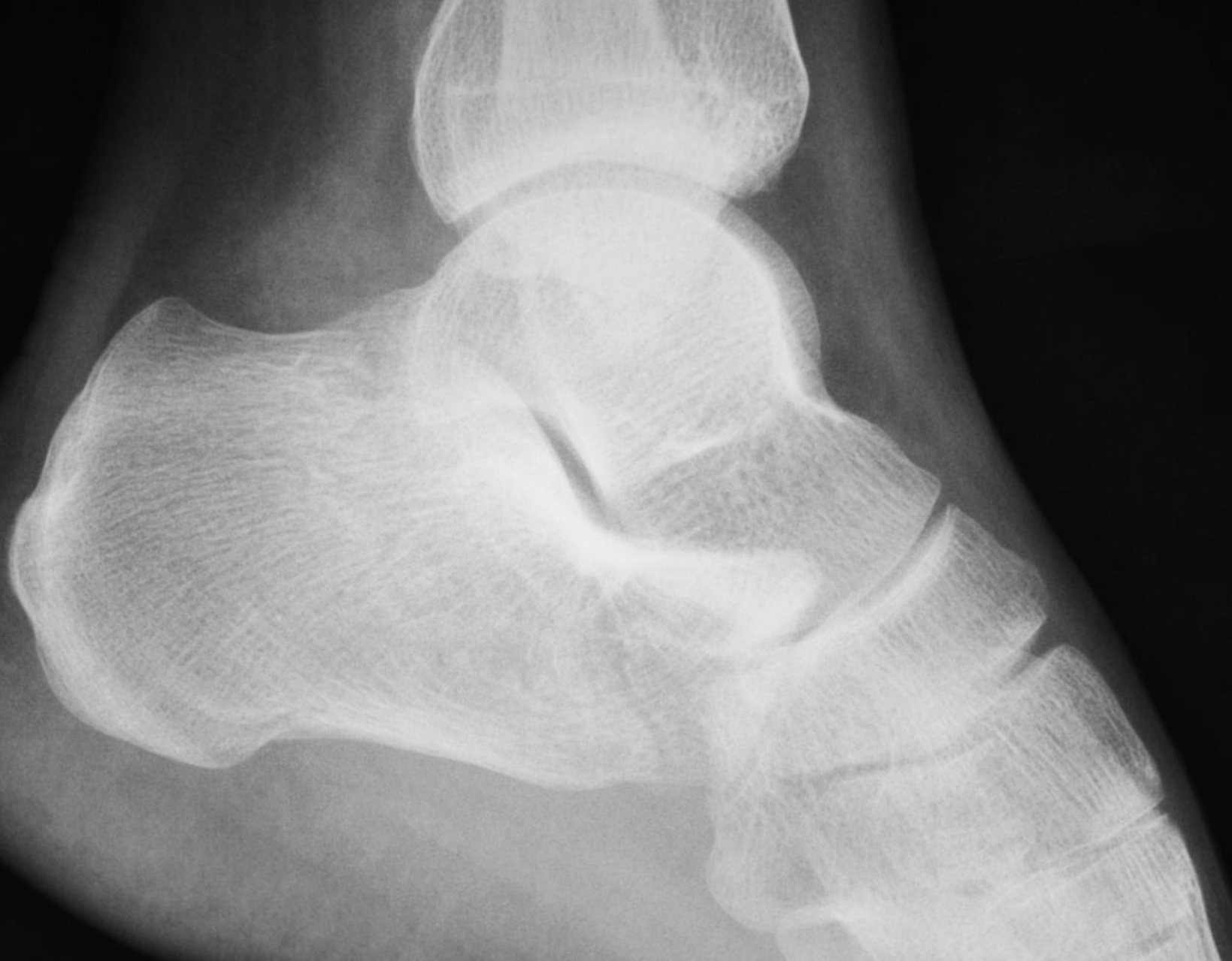



仁濟醫院

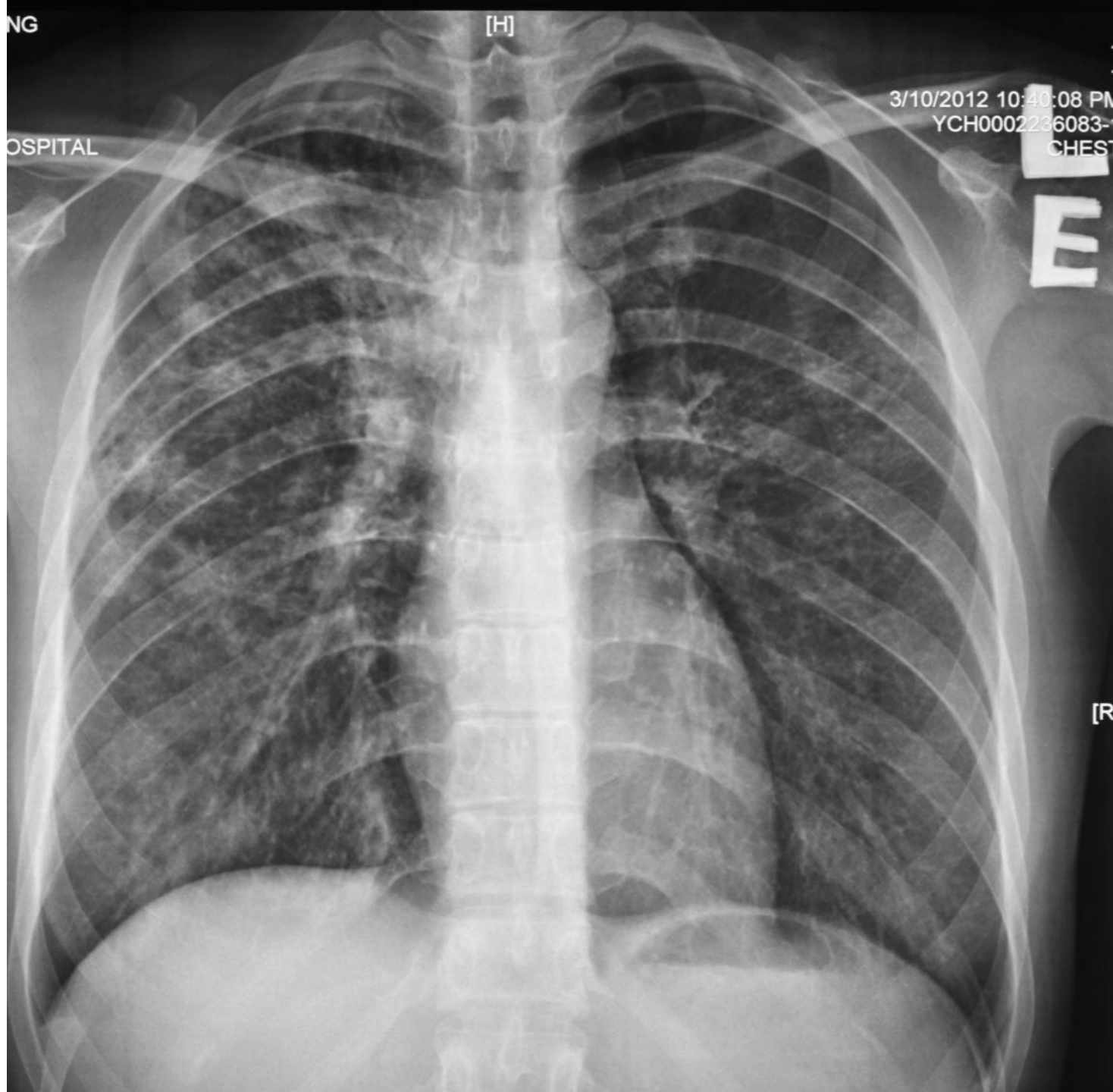


1



M/29, left ankle pain after fell from height

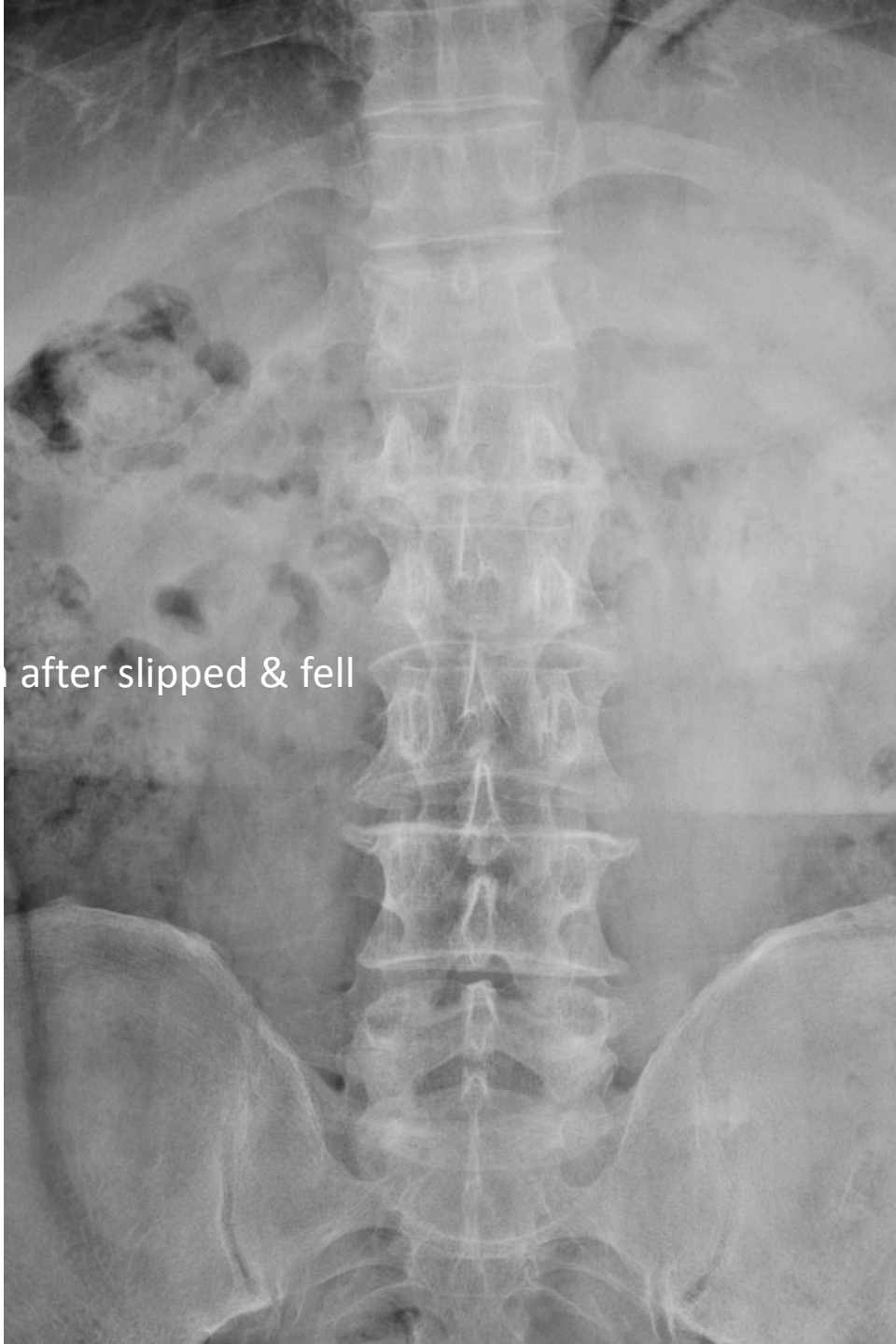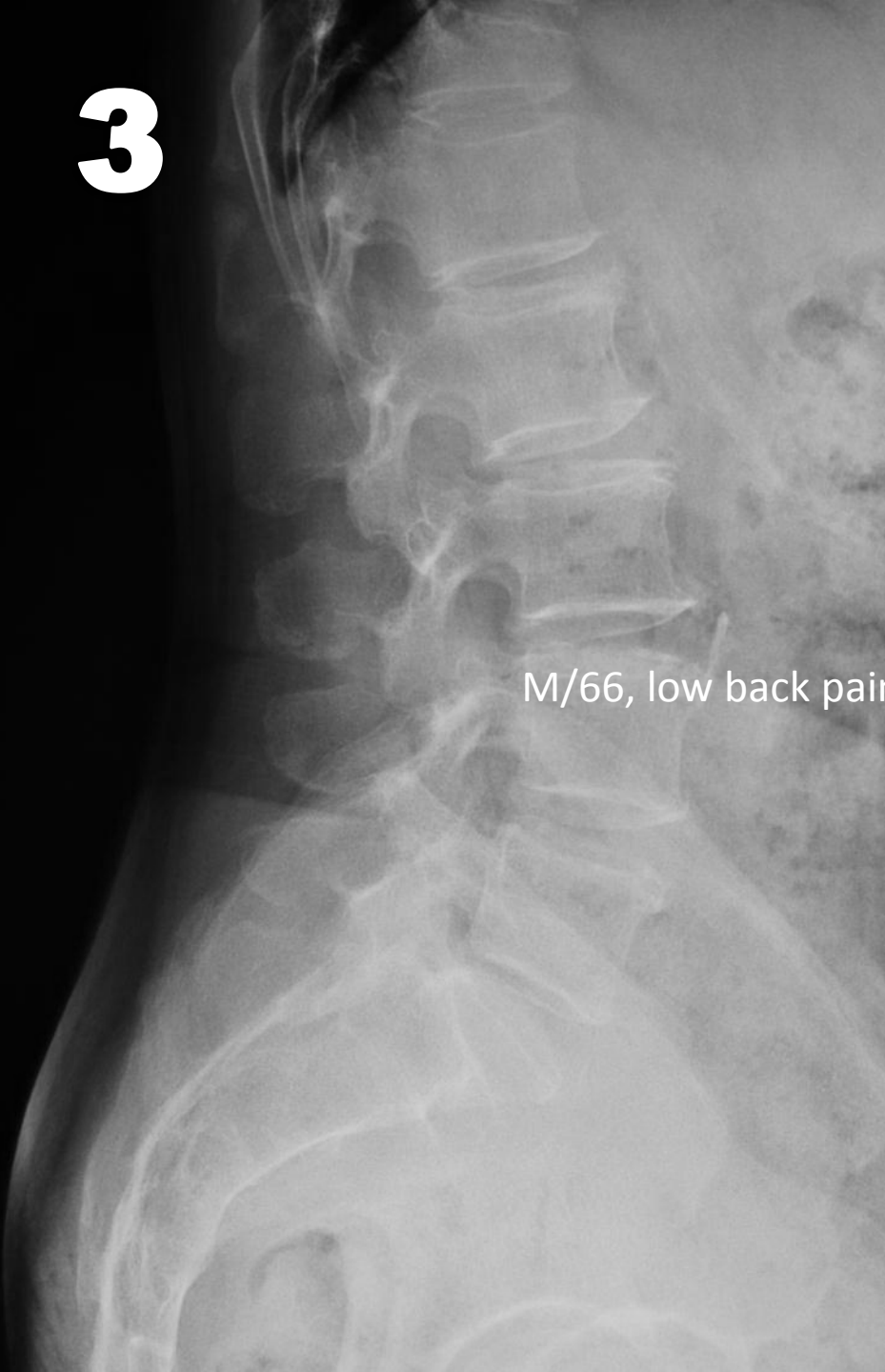2



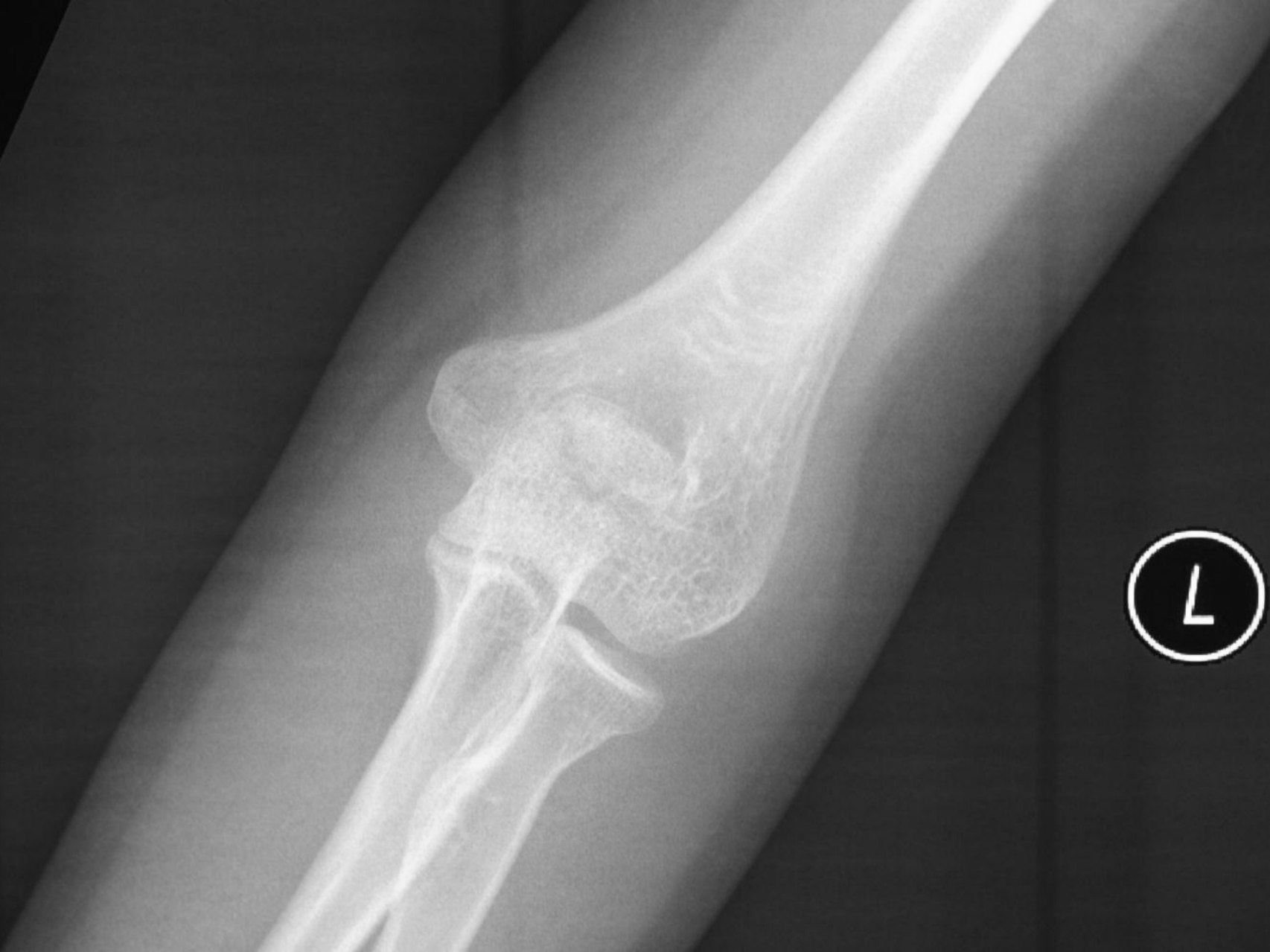F/23, cough for 2/12

3

M/66, low back pain after slipped & fell

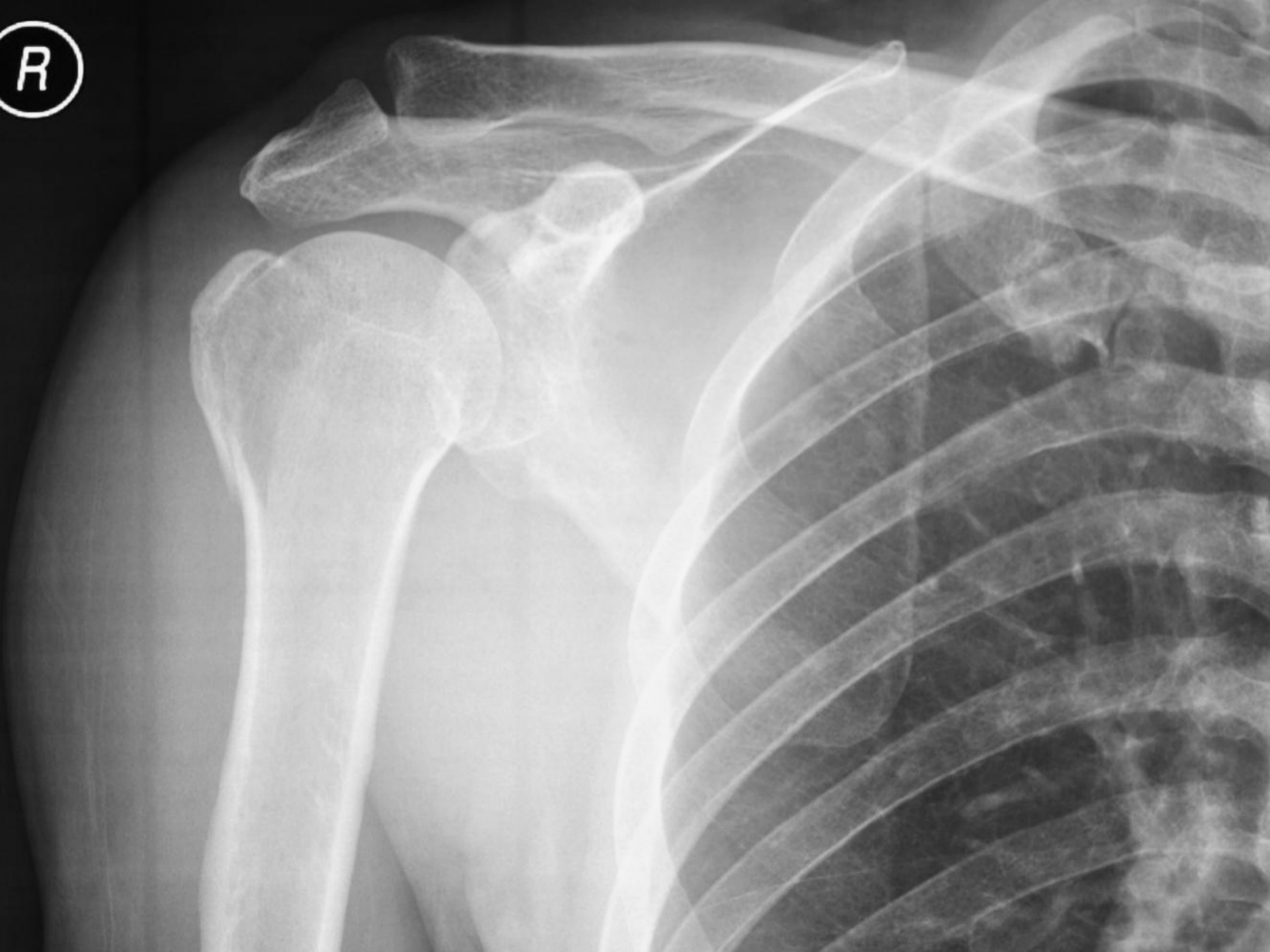

4



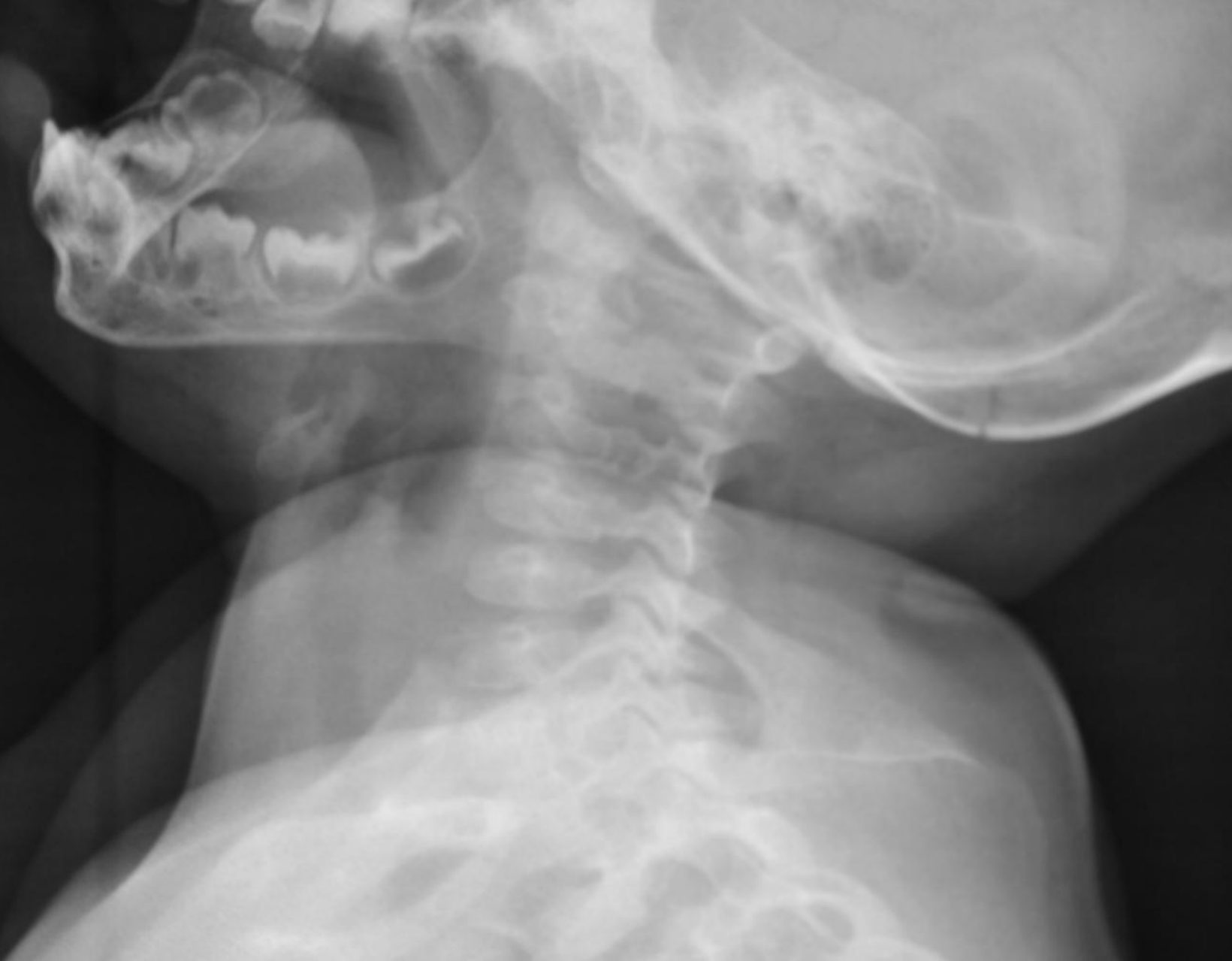F/42, left elbow pain after slipped & fell

5[®] R



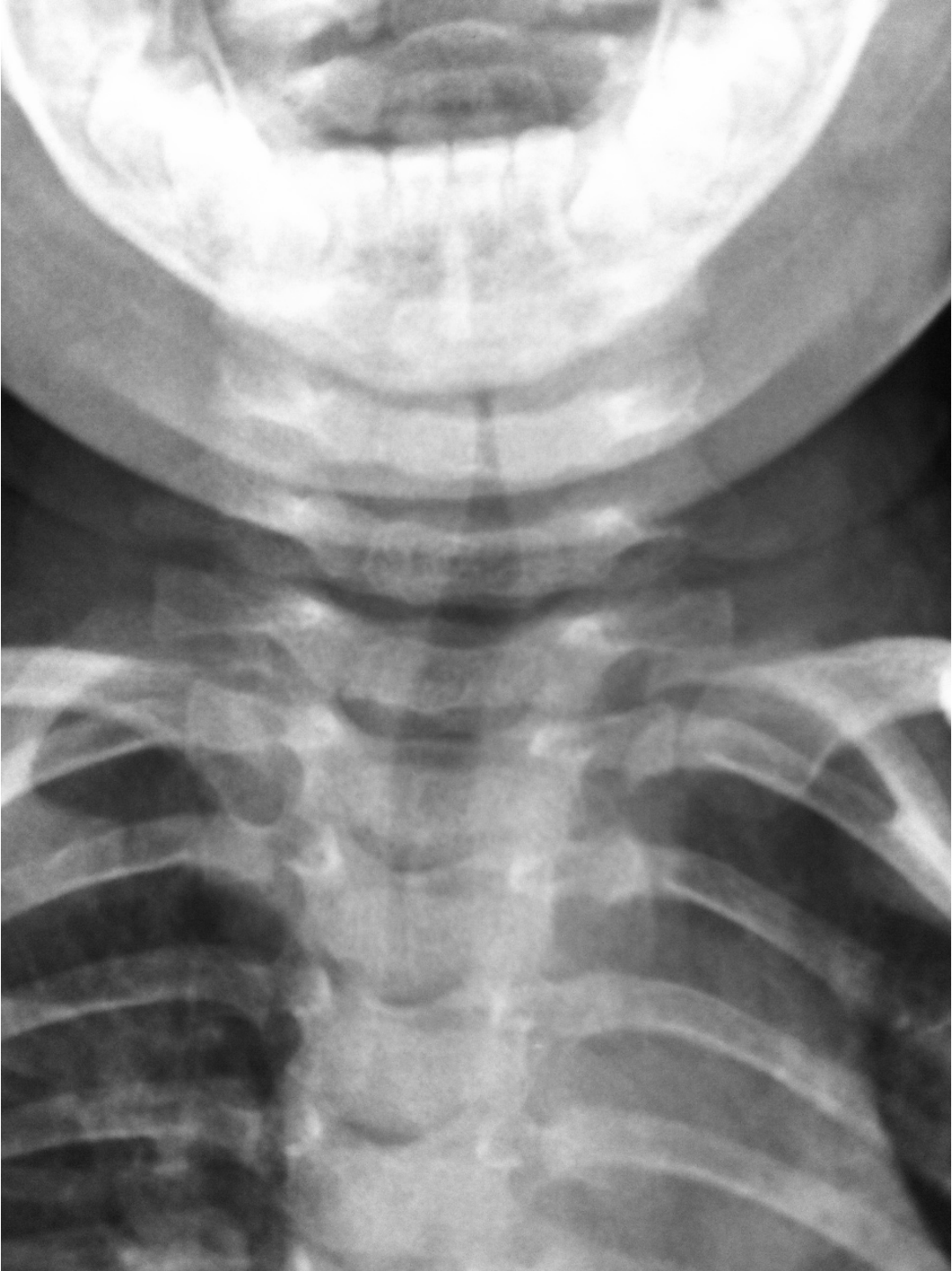M/45, unable to move right upper limb after contusion injury

6



M/1, fever & noisy breathing

6



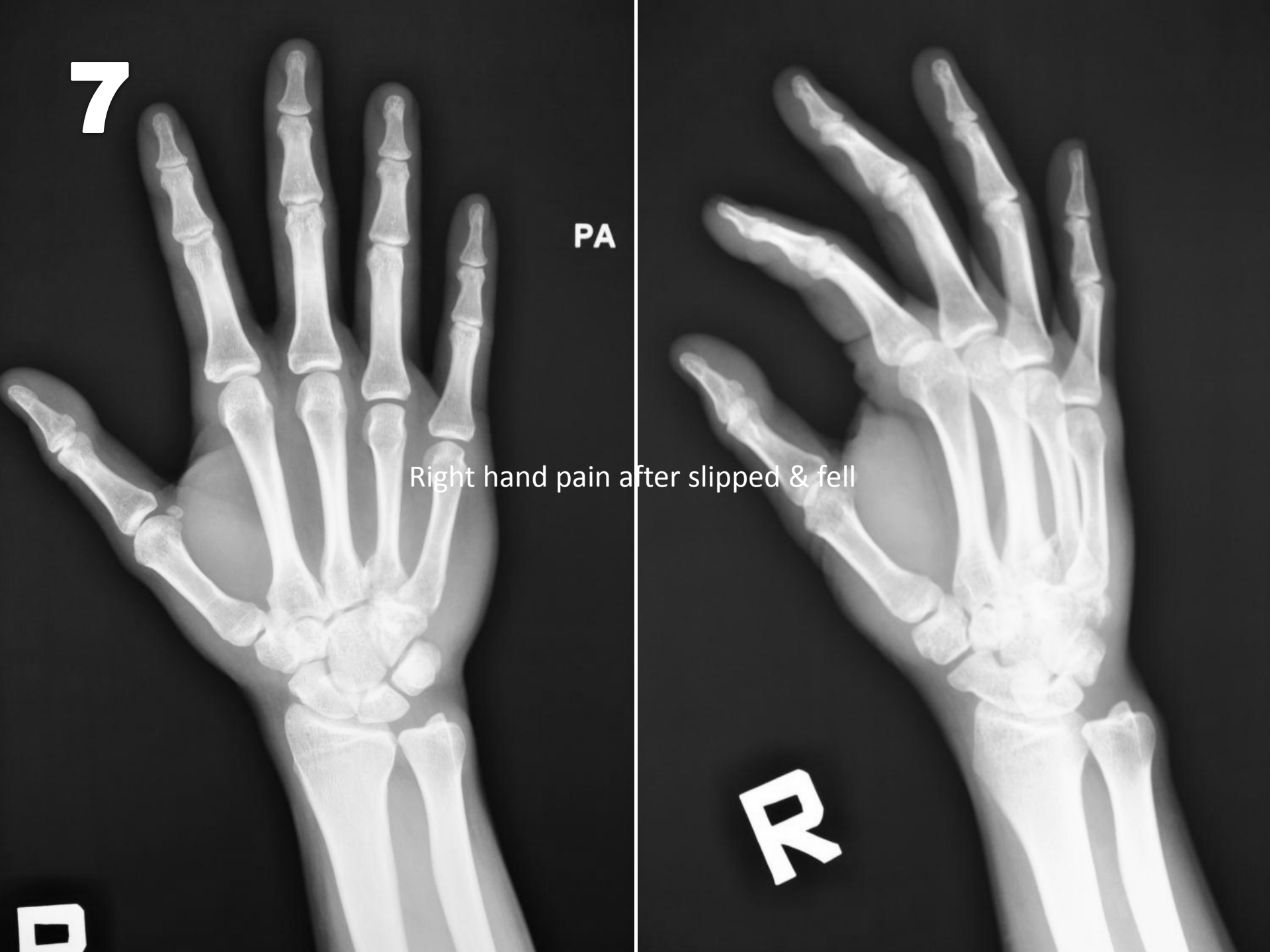
7

PA

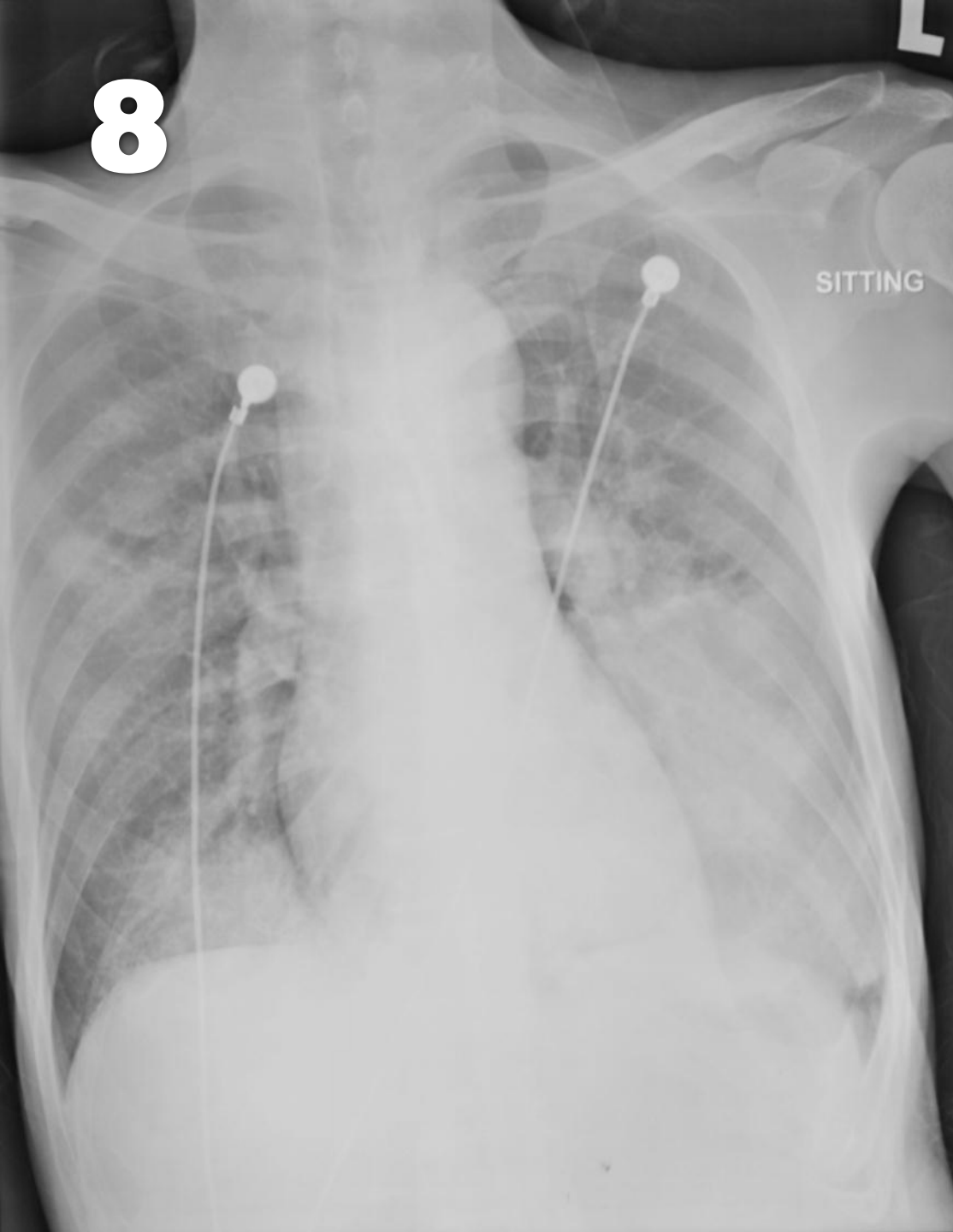
Right hand pain after slipped & fell

D

R



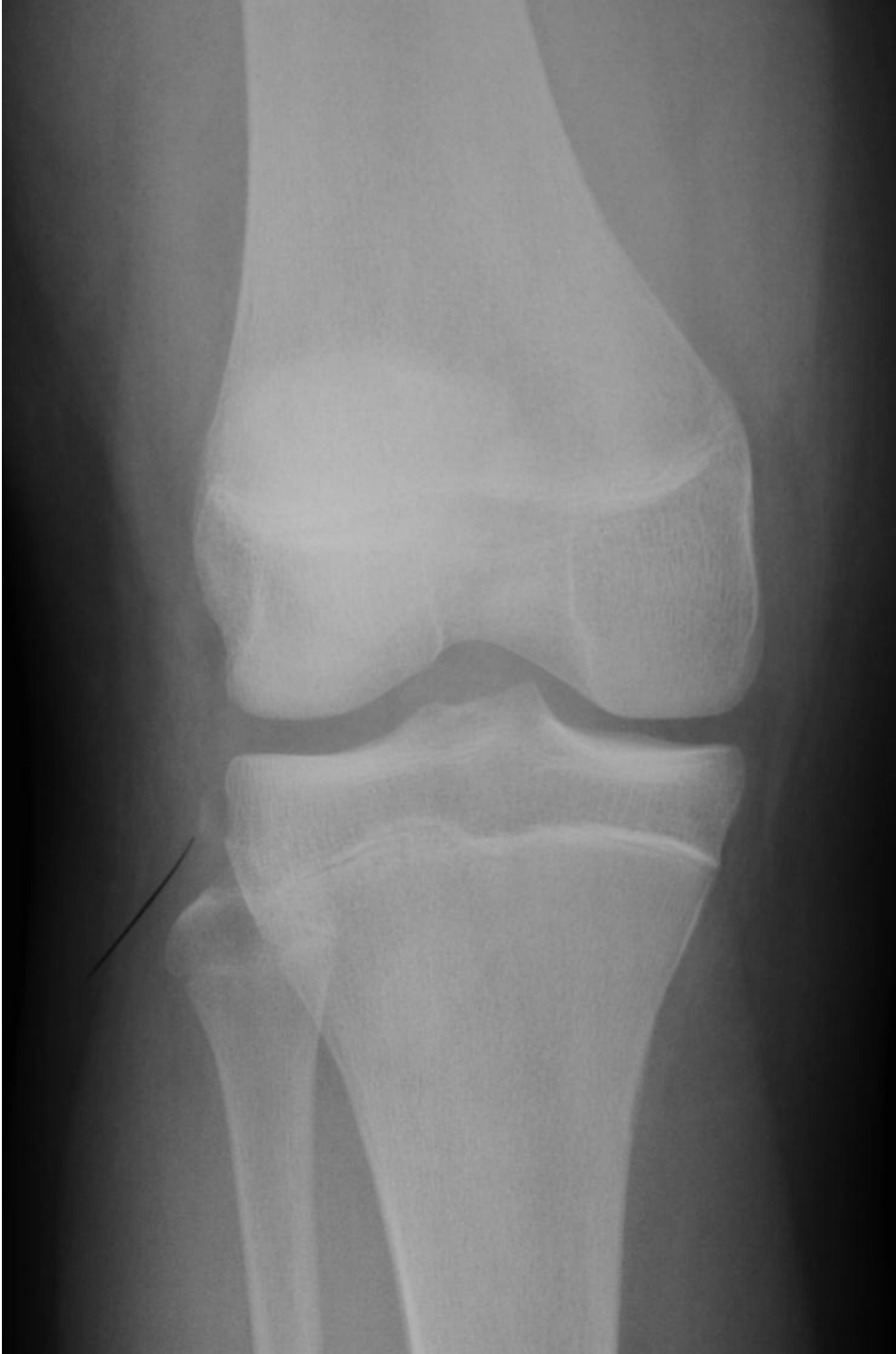8



SITTING

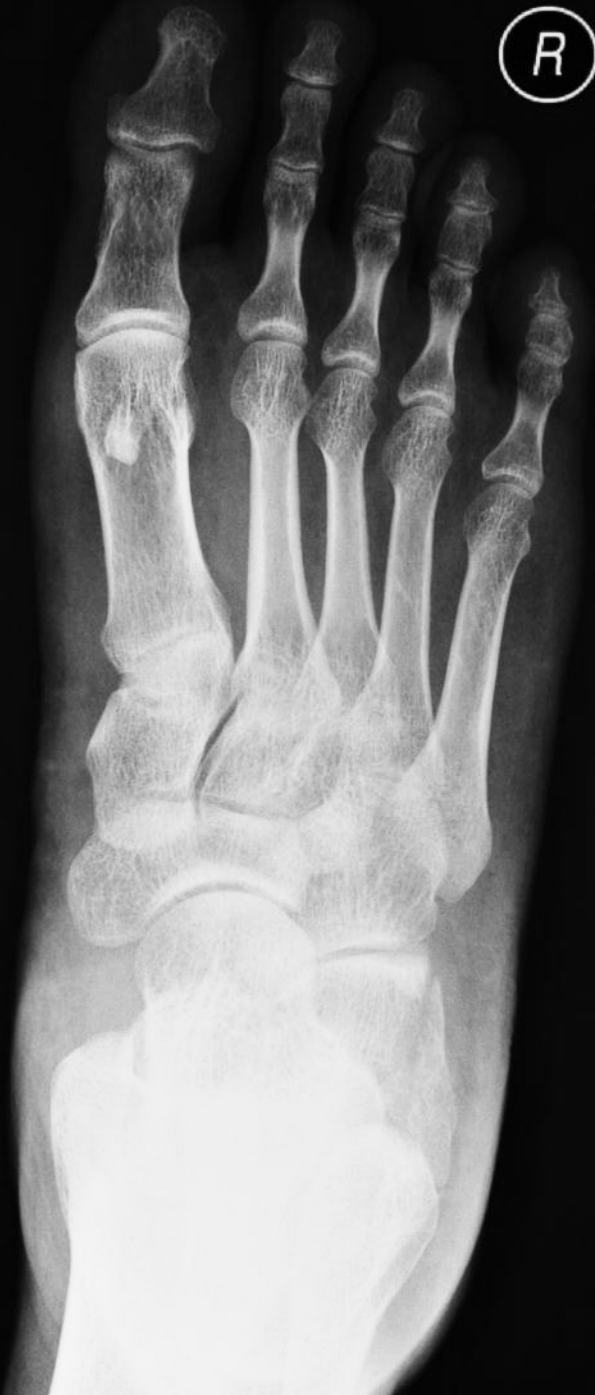M/50, cough & shortness of breath

9



M/14, sprained right knee

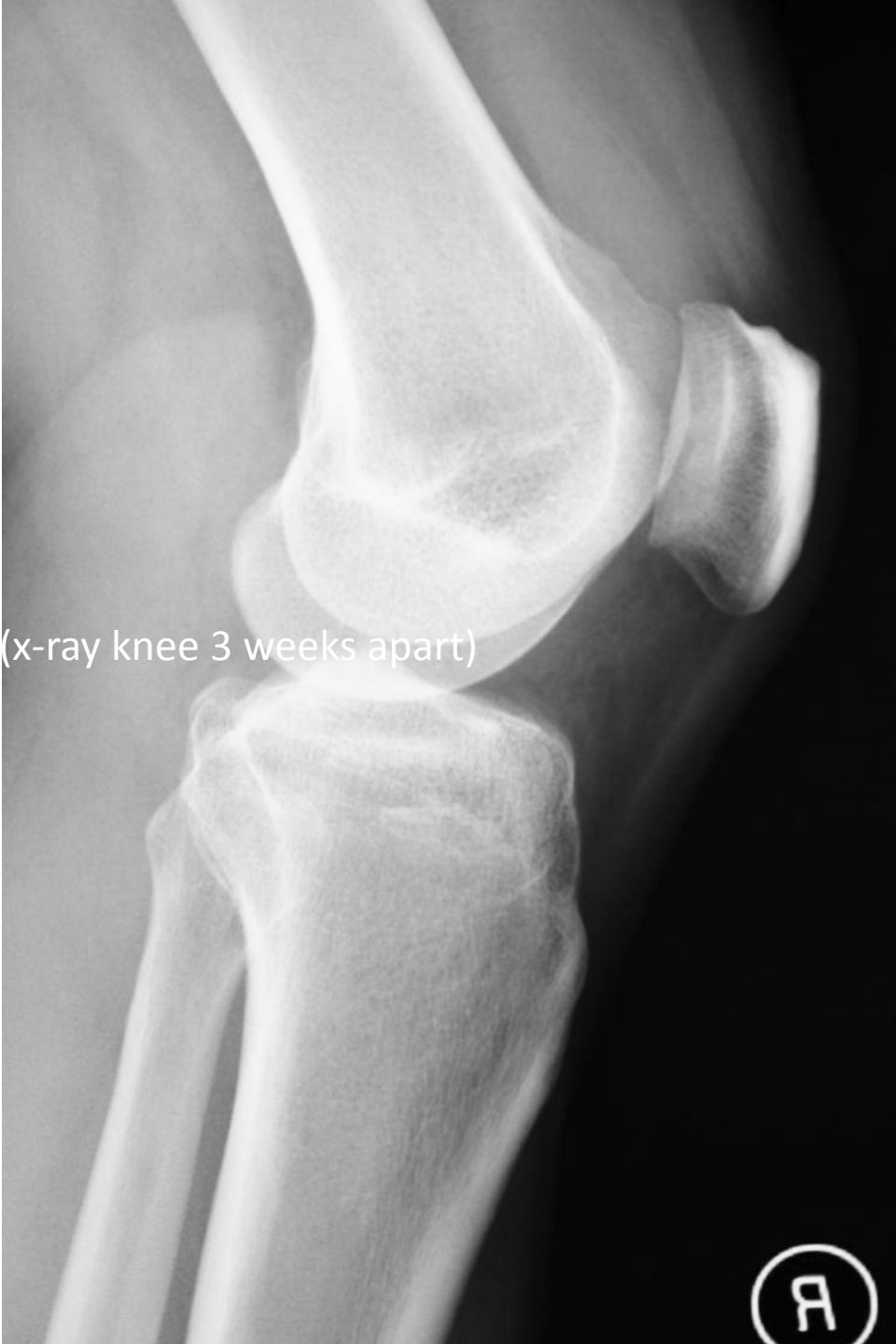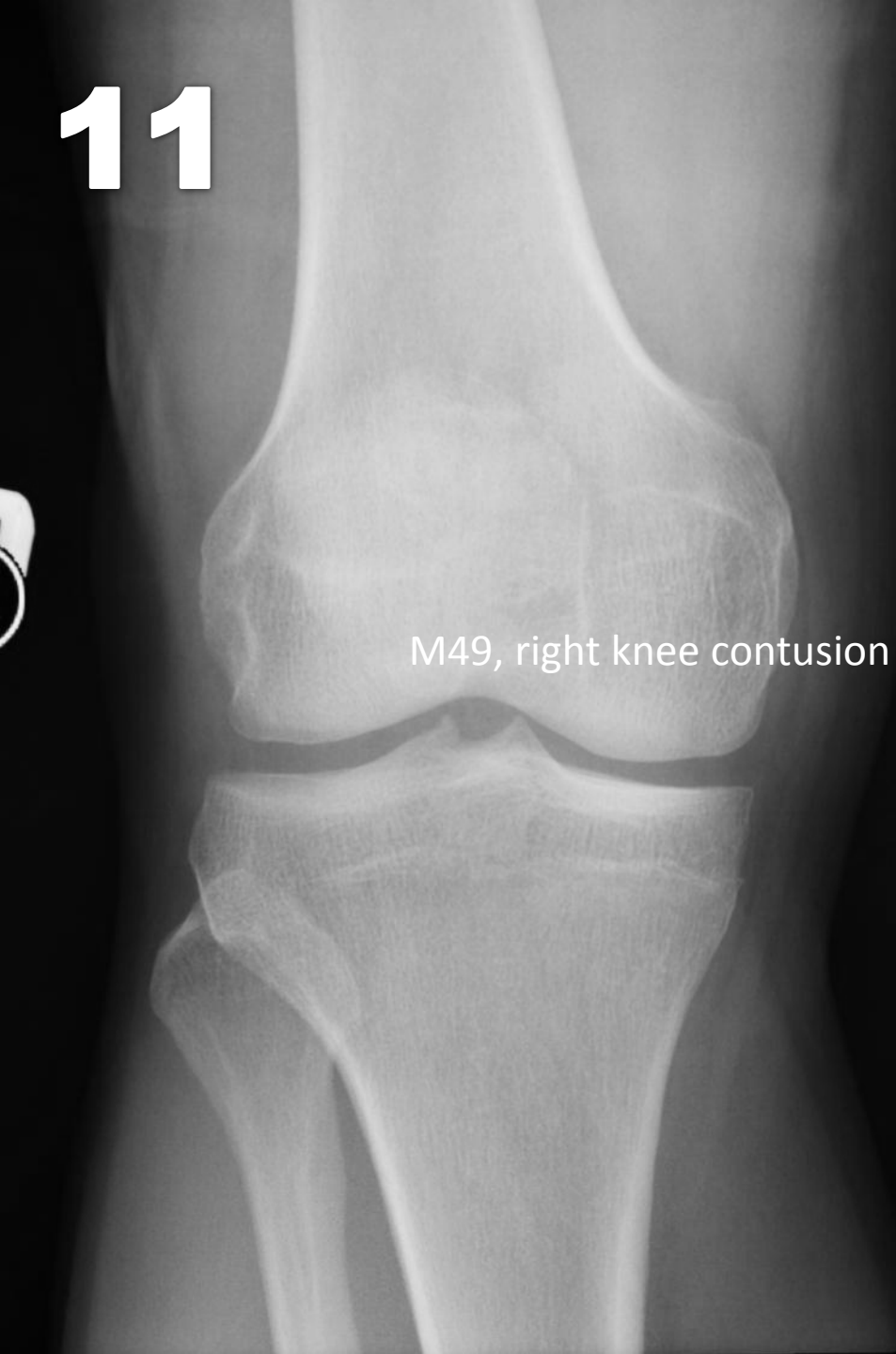
10



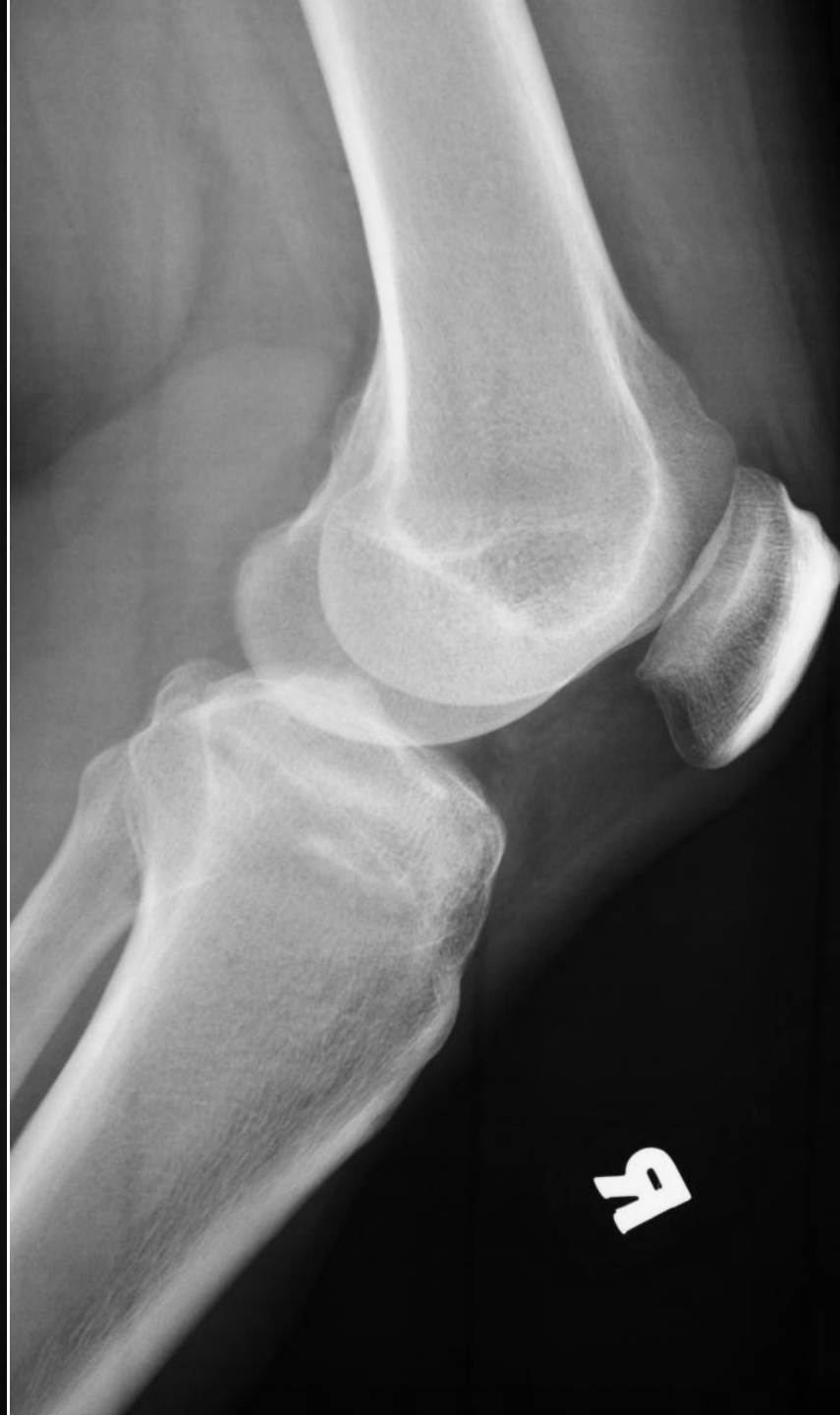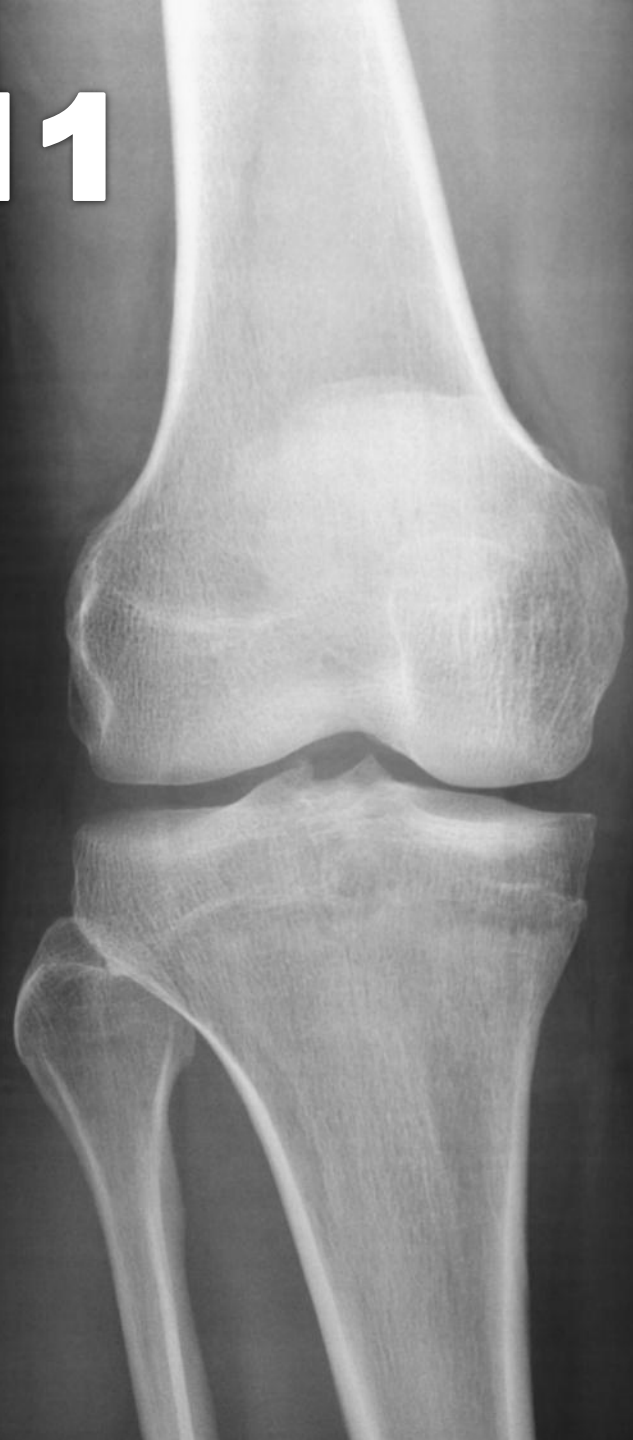M/44, sprained right ankle

11

M49, right knee contusion (x-ray knee 3 weeks apart)

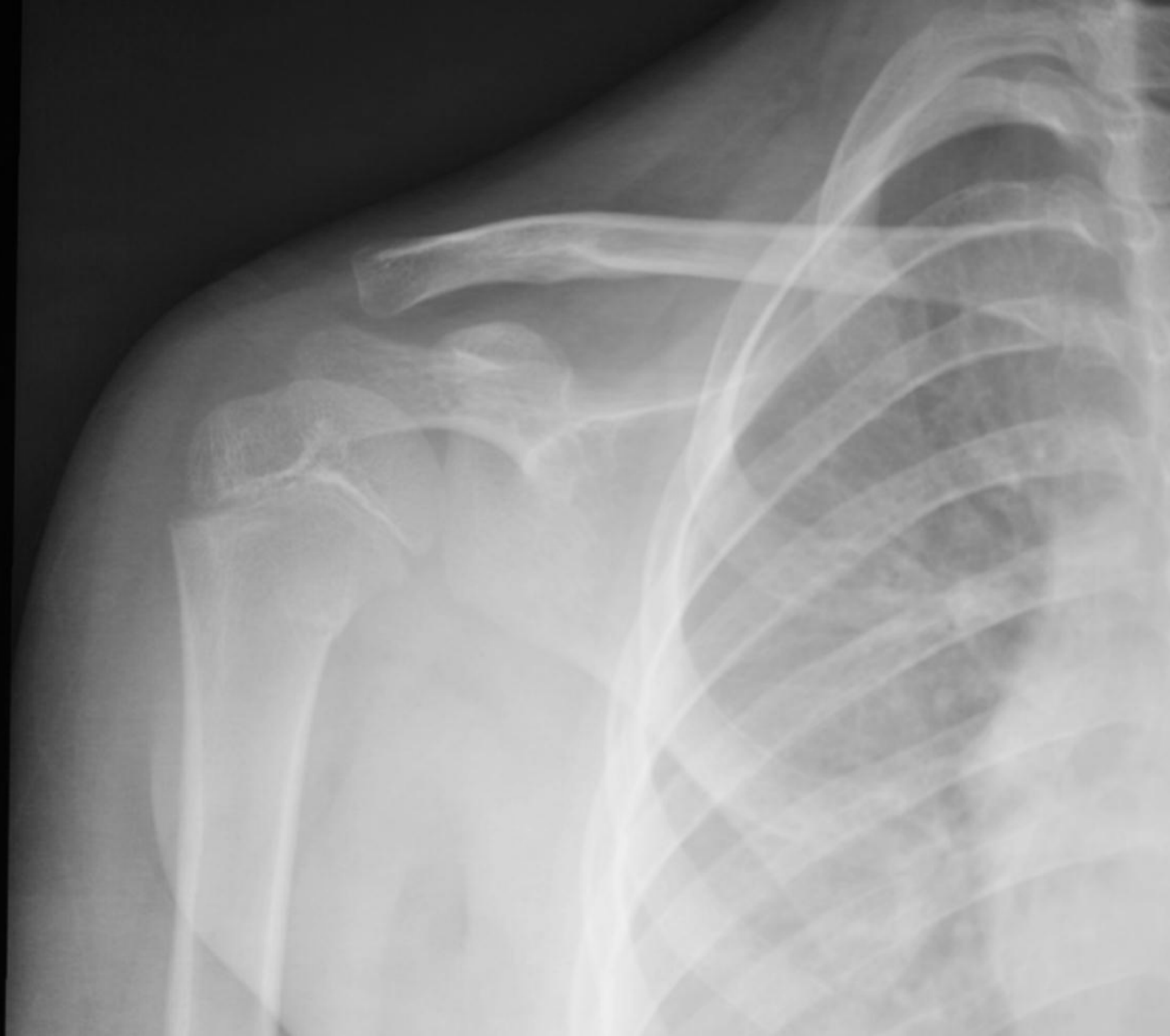

11



R

12

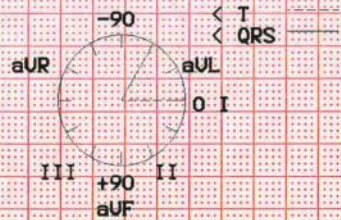


F/9, right upper limb pain after slipped & fell

14

Measurement Results:

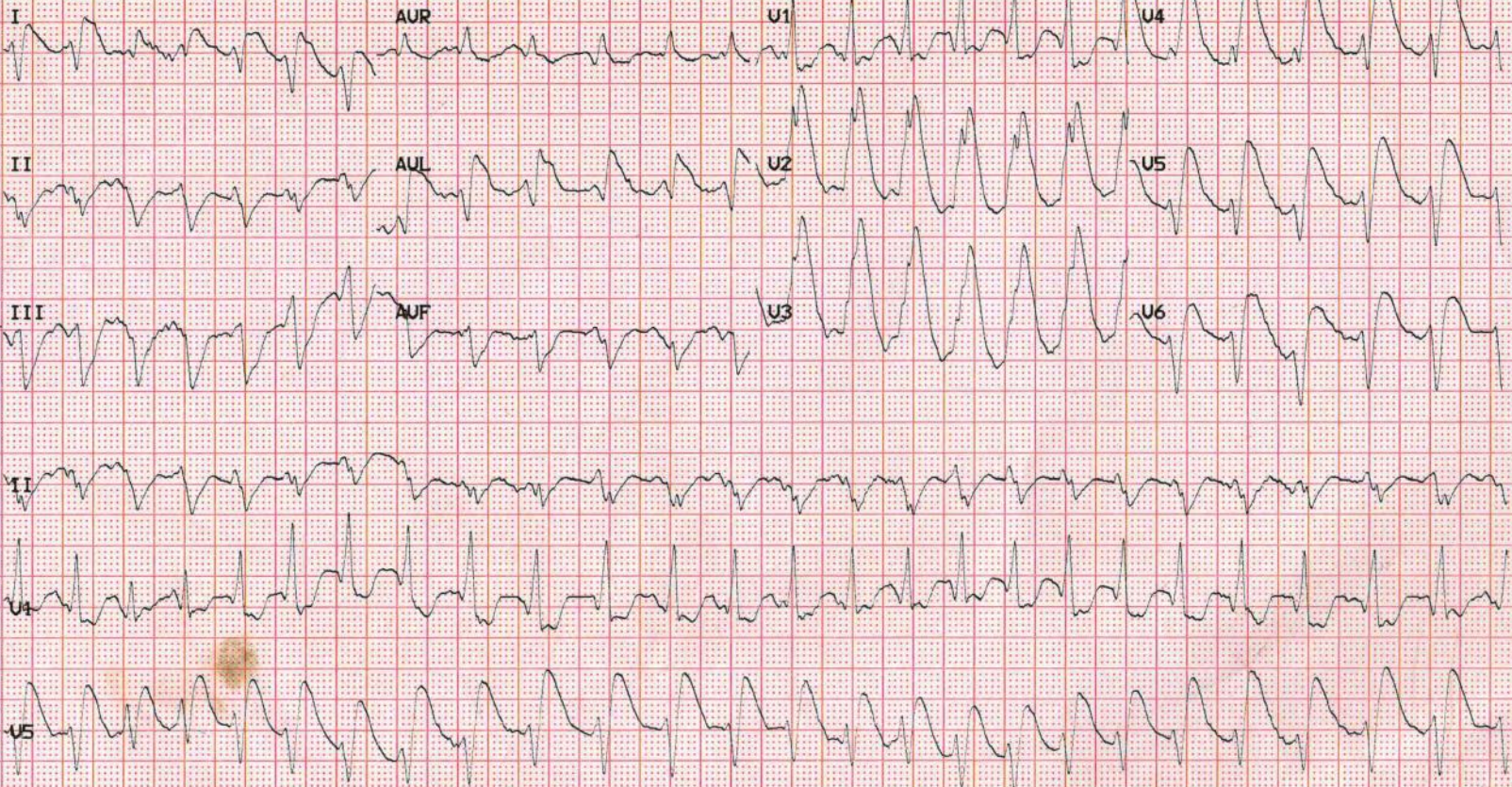
QRS		314 ms
QT/QTcB	326 / 481 ms	
PR	(258) ms	
P	(130) ms	
RR/PP	460 / 460 ms	
P/QRS/T	-60 / 0 degrees	
QTd/QTcBD	66 / 97 ms	
Sokolow	0.5 mU	
NK	2	



Interpretation:
 persistent ventricular rh
 Note ! temporary signal i
 Note ! insufficient simil
 probably abnormal ECG

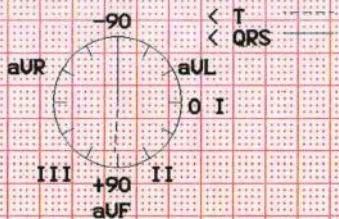
M/49, chest pain

Unconfirmed report.



15

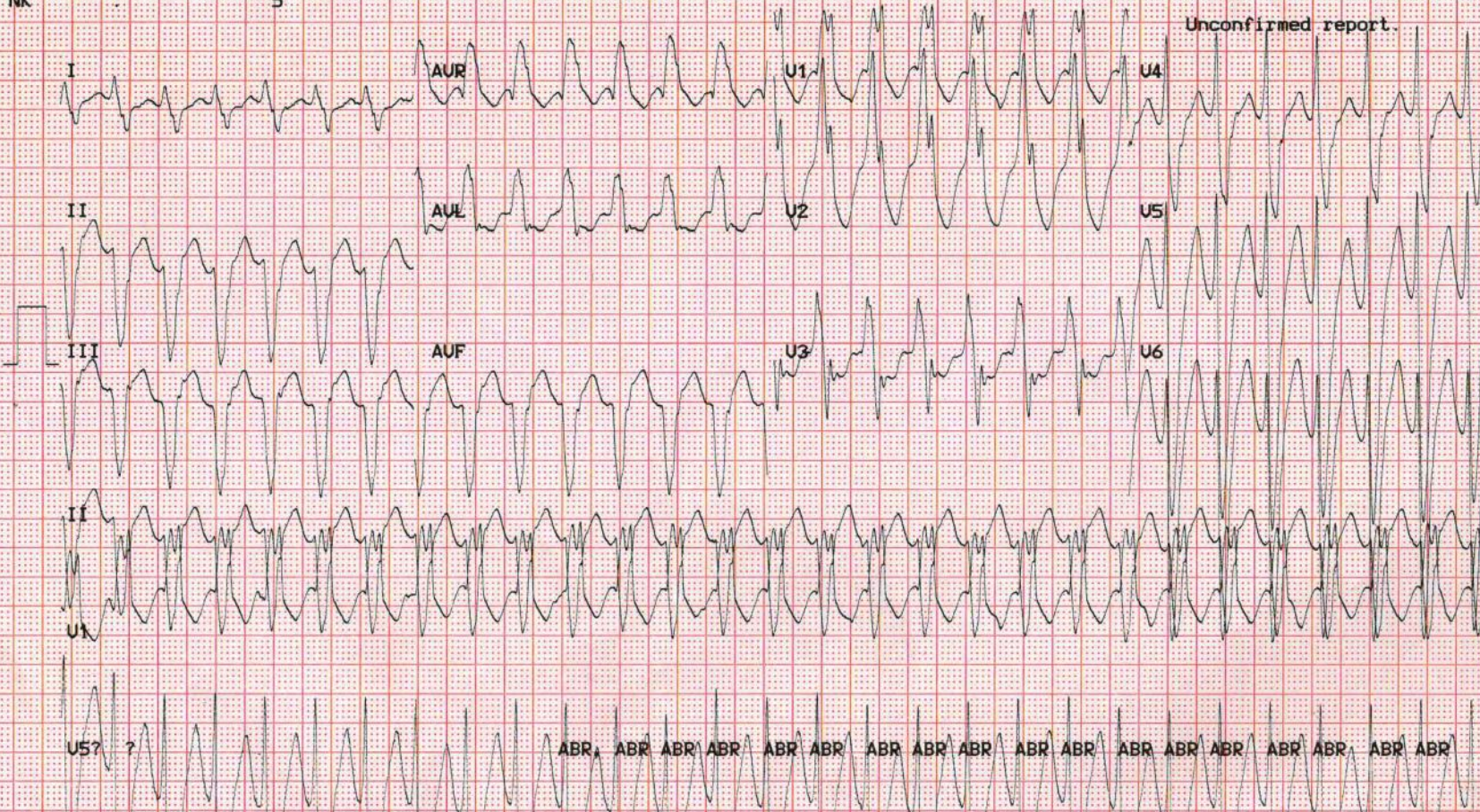
M sur Results:
 QRS 168 ms
 QT/QTcB : 266 / 448 ms
 PR : (144) ms
 P : (120) ms
 RR/PP : 352 / 350 ms
 P/QRS/T : / -90/ 95 degrees
 QTD/QTcBD: 66 / 111 ms
 Sokolow : mU
 NK : 5



Interpretation: 1
 persistent ventricular rhythm
 probably abnormal ECG

M/68, dizziness

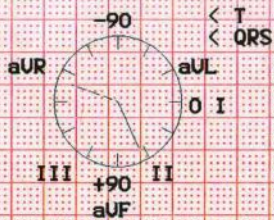
Unconfirmed report.



16

Measurements results:

QRS	70 ms
QT/QTcB	290 / 470 ms
PR	(180) ms
P	(154) ms
RR/PP	380 / 380 ms
P/QRS/T	/ 65/-160 degrees
QTd/QTcBd	40 / 65 ms
Sokolow	4.8 mV
NK	23



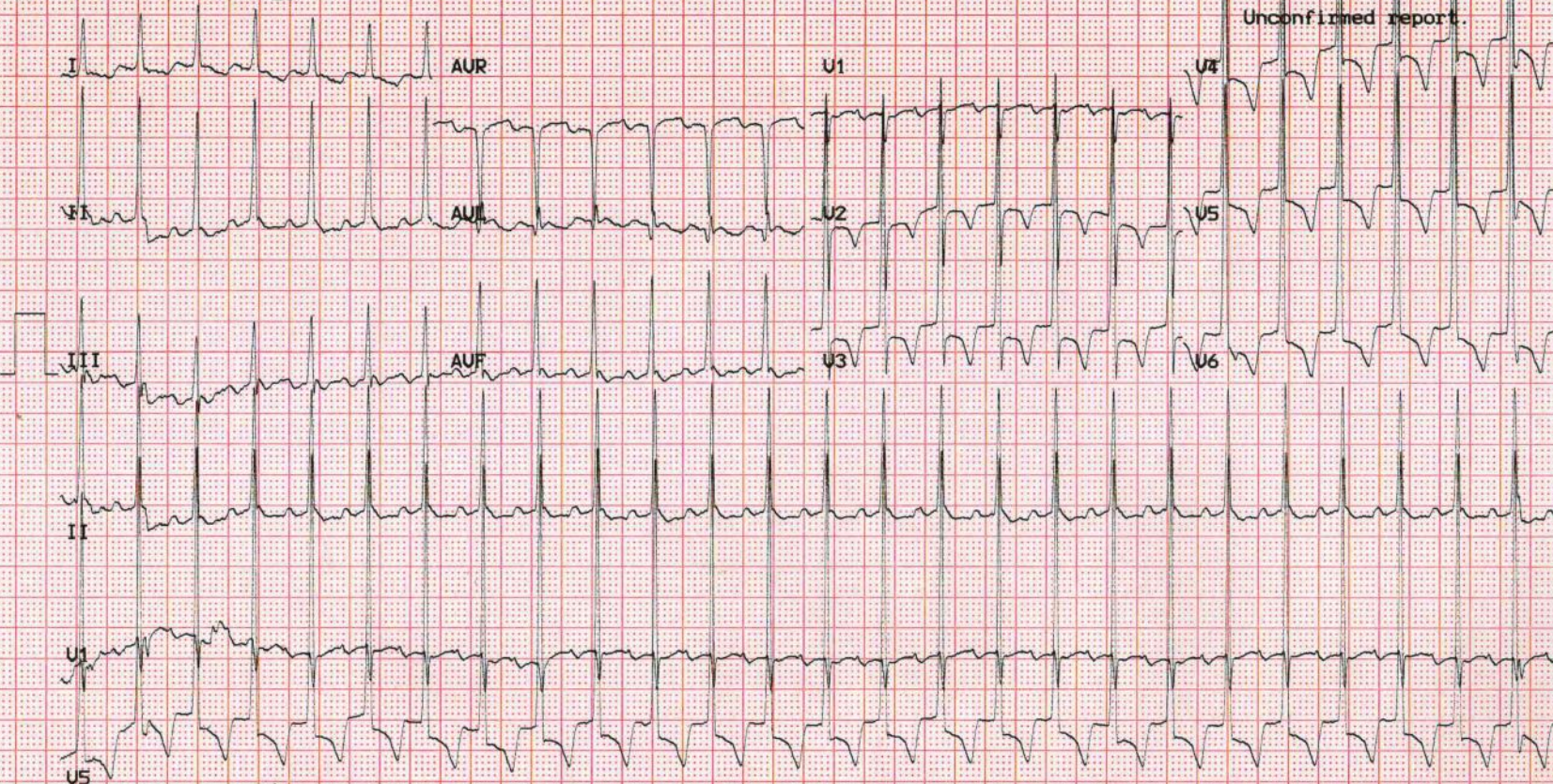
F/81, chest pain after slipped & fell

1

HR 157 bpm


hypertrophy
 ST depression (lateral, anterior)
 large negative T-wave (lateral, anterior)
 negative T-wave (inferior)
 R/S inversion area between U1 and U2
 probably abnormal ECG

Unconfirmed report.

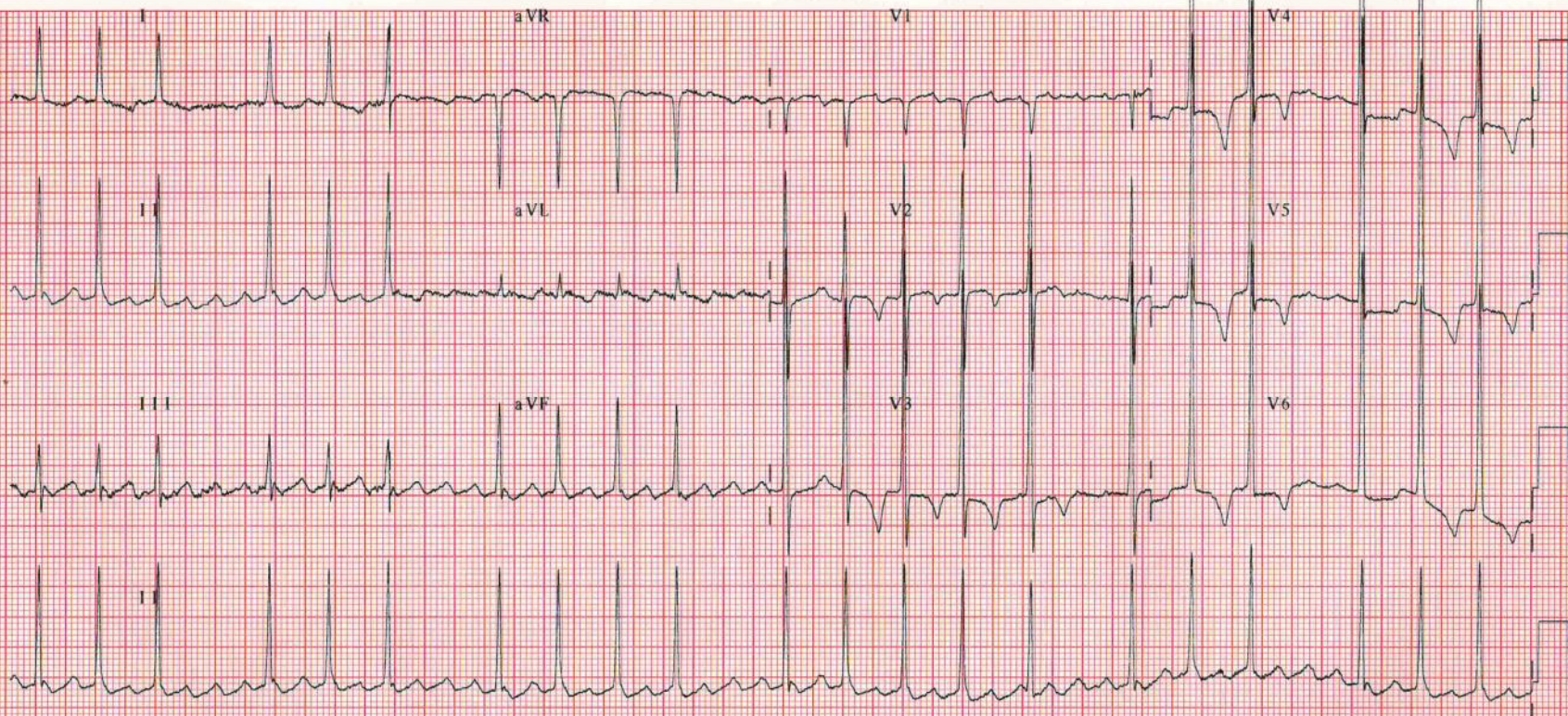


16

18-38



②

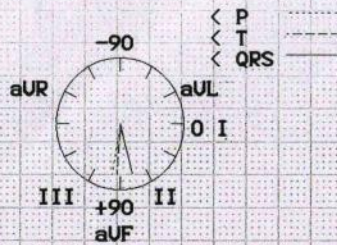


100 by Dr. W. C. C. HR 30 bpm

17

Measurement results:

QRS : 98 ms
 QT/QTcB : 568 / 408 ms
 PR : 410 ms
 P : 116 ms
 RR/PP : 1936 / 1935 ms
 P/QRS/T : 100 / 75 / 95 degrees
 QTD/QTcBD : 94 / 68 ms
 Sokolow : 2.5 mV
 NK : 3

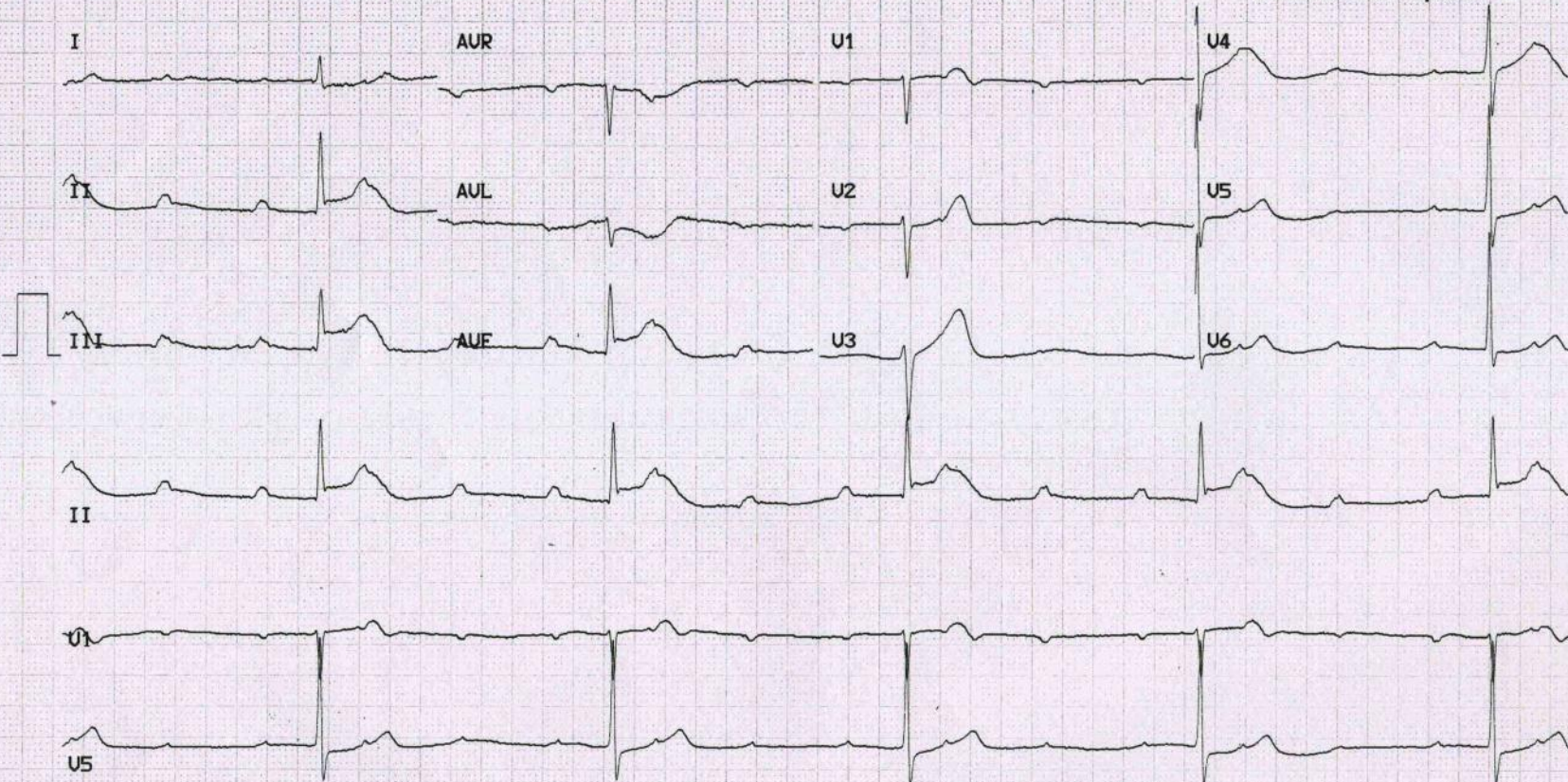


Interpretation:

1st degree A-U block
 sinus bradycardia
 ST-segment depression (lateral)
 ST-segment elevation (inferior)
 T-wave near baseline (lateral)
 probably abnormal ECG

M/84, found collapse

Unconfirmed report.



loanby Dr. Lok CL.

18

. AGE IS NOT ENTERED, ASSUMED TO BE 50 YEARS OLD FOR PURPOSE OF ECG INTERPRETATION
 Rate 106 . ATRIAL FIBRILLATION, V-RATE 66-147.....var'd rate, irreg atrial activity
 PR . REPOL ABNRM SUGGESTS ISCHEMIA, ANT-LAT LEADS.....ST dep, T neg, I aVL V2-V6
 QRSD 86
 QT 356
 QTc 473

--AXIS--
 P
 QRS 73
 T 99

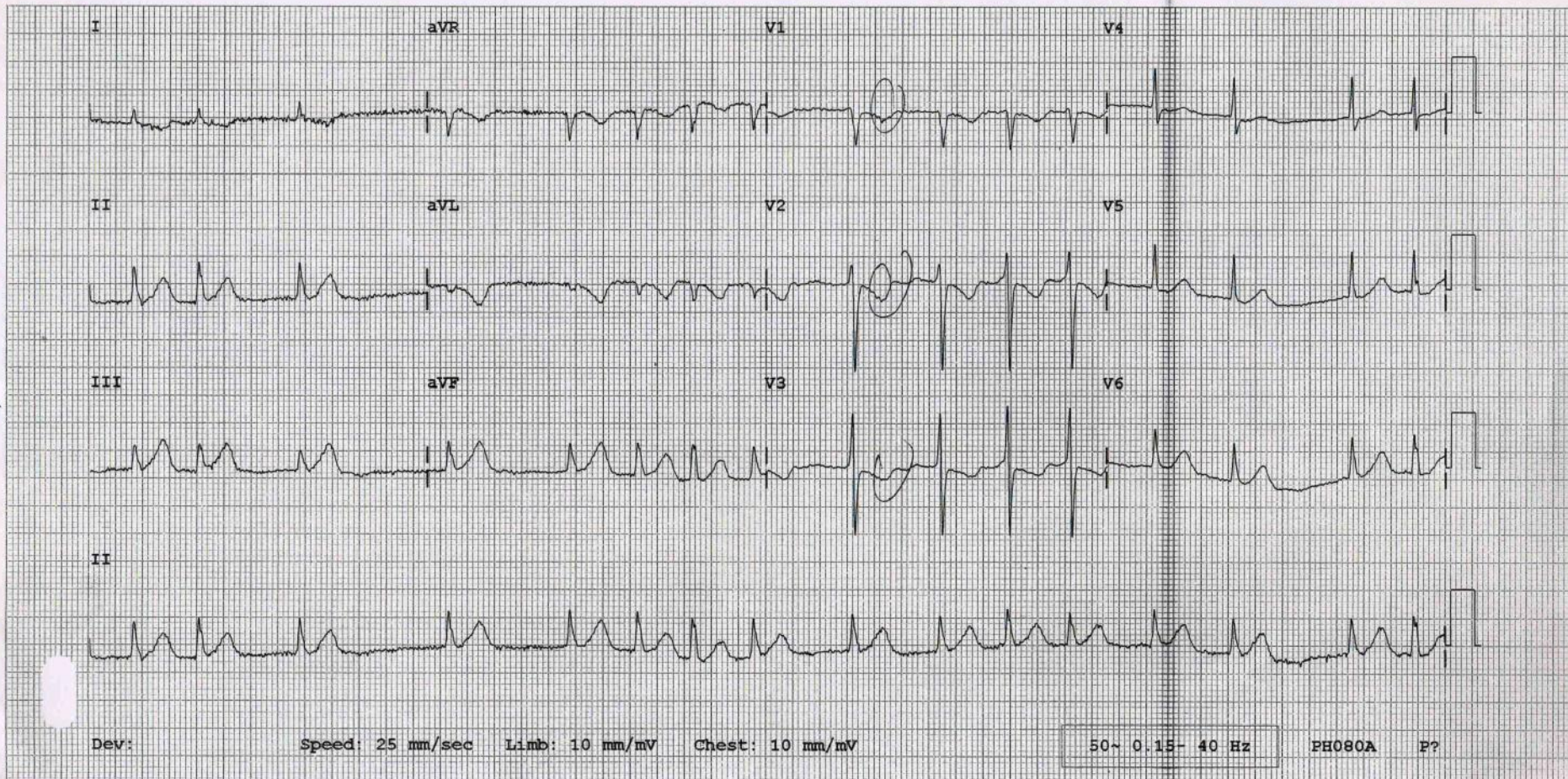
- ABNORMAL ECG -

6

F/80, palpitation

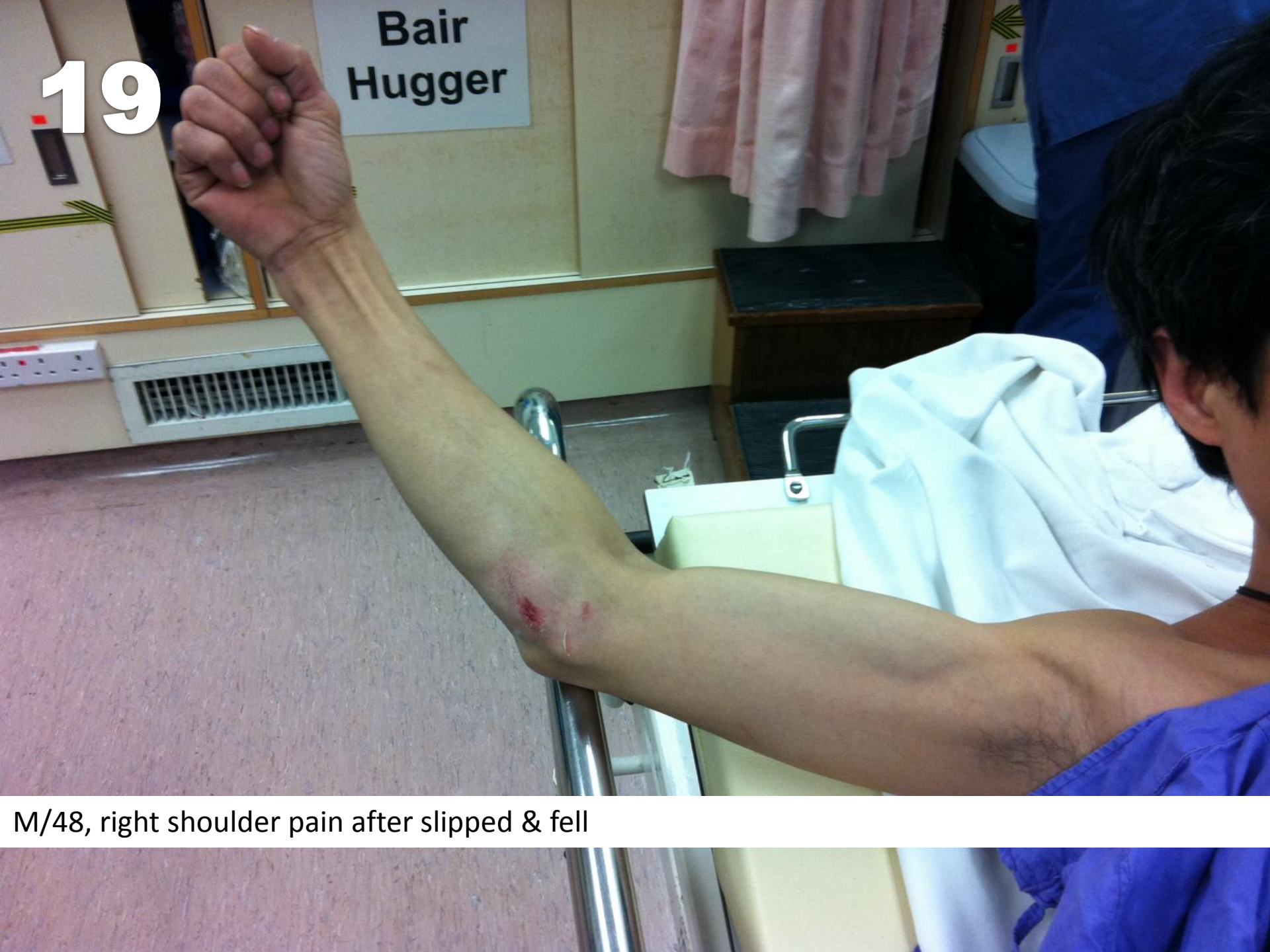08/11/2011 12:30 EP1

Unconfirmed Diagnosis



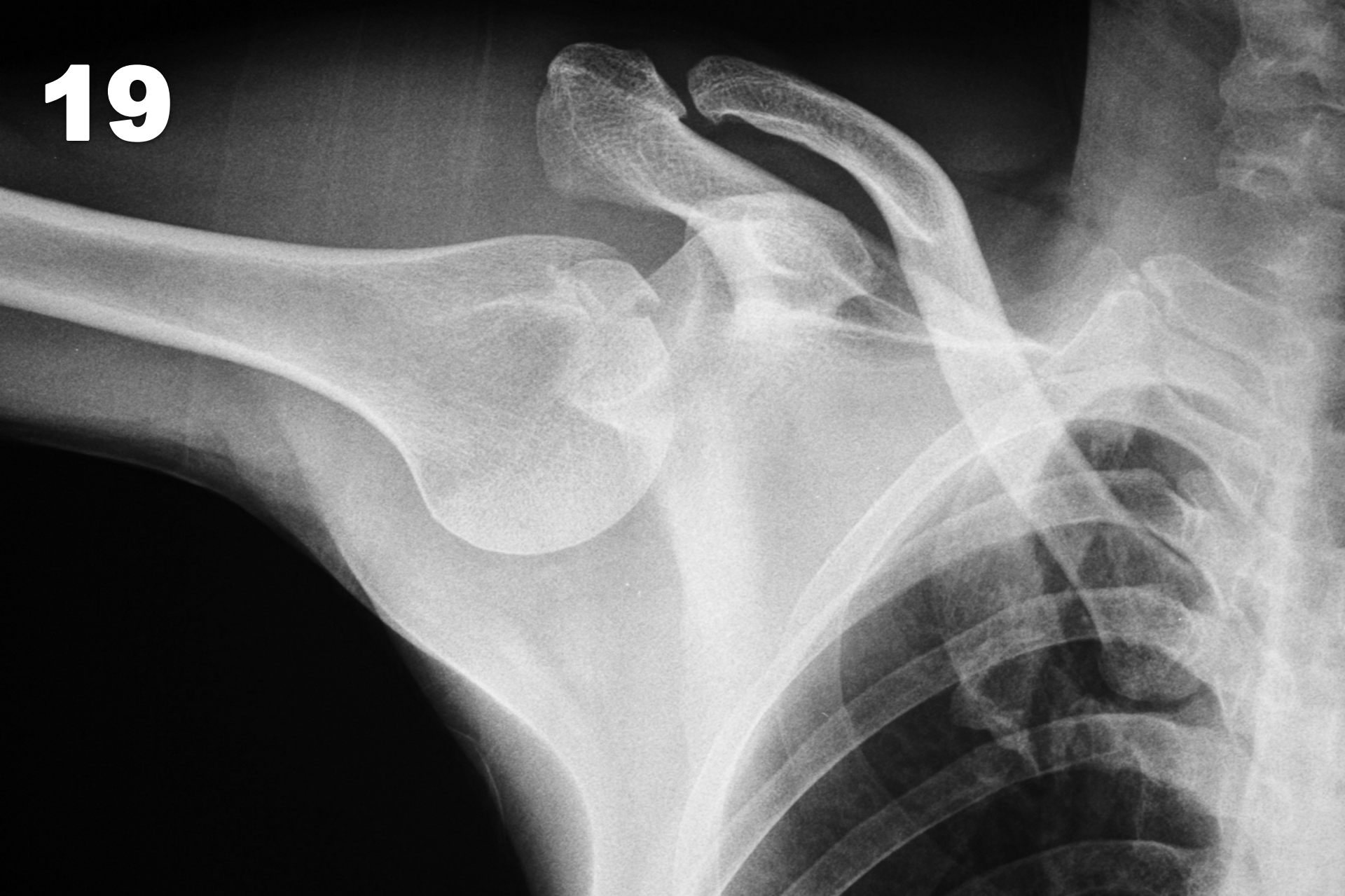19

Bair
Hugger

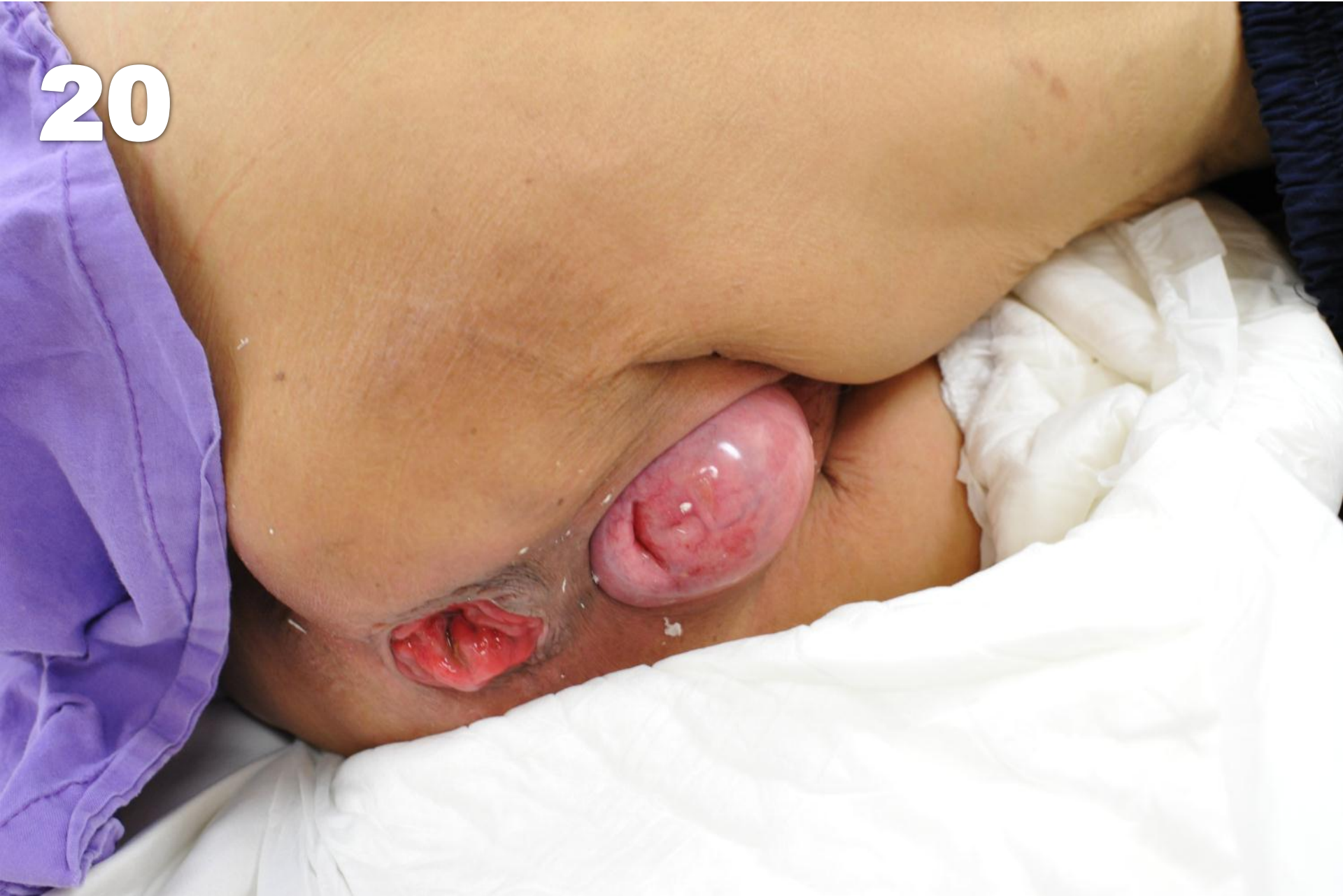

M/48, right shoulder pain after slipped & fell

19



20



F/72, rectal discomfort

Answers

1. Fracture calcaneum
2. Pulmonary TB
3. Collapse fracture T12
4. Fracture olecranon
5. Fracture greater tuberosity
6. Croup with steeple sign
7. Fracture 4th MT base & hamate
8. Pneumonia
9. Second fracture
10. Fracture calcaneum
11. Fracture tibial condyle
12. Humeral greenstick fracture
13. VT
14. Anterolateral MI, ST
15. VT
16. Atrial flutter, 2:1 HB
17. Inferior MI, CHB
18. Inferior MI, AF
19. Inferior shoulder dislocation
20. Rectal & vaginal prolapse